

Research Article

Open Access

Mohsen Eshraghi, Ladan Shahmoradi, Mahdiieh Ghoddoosi, Seyed Jafar Adnani Sadati*

Diagnosis of Primary Hydatid Cyst of Thyroid Gland: A Case Report

<https://doi.org/10.1515/bmc-2019-0013>

received December 16, 2018; accepted March 25, 2019.

Abstract: A 34-year-old female patient was presented to the general surgery clinic of the hospital complaining of a growing tangible swelling in her neck. In physical examination, the patient had two palpable soft nodules in the left lobe of the thyroid which hadn't invaded the surrounding tissues. The function of thyroid gland was normal and fine needle aspiration (FNA) result reported it benign. The patient went through a left lobectomy and isthmectomy. The histopathology report concluded a nodular hyperplasia and a Hydatid cyst. After surgery, the patient was examined searching for any other organs cyst, but there were no cystic lesion in the cranial, thoracic and abdominal cavities. Accordingly, the case was a primary thyroid hydatid cyst, which is rare, even in endemic regions like Iran.

Keywords: Case report; Histopathology; Isthmectomy; Hydatid cyst; Thyroid gland.

Introduction

Cystic hydatid disease or hydatidosis is an endemic parasitic disease in human populations in Iran and some parts of the world such as the Mediterranean countries, Middle East, South America, India, Iceland, Australia, New Zealand, and South Africa [1, 2]. It is caused by the larval stage of cestoda (tapeworms) of *Echinococcus granulosus*. In the life cycle of *E. granulosus*, dogs play the role of

definitive host, herbivores are considered intermediate hosts (inclusive of: Sheep, Goat, Pig, Cattle, Camel, etc.). Humans sometimes act as accidental intermediate host [3].

Larvae emerge from the eggs in the intestine; then they invade the blood vessels where they can emigrate in to every part of the body. The common destination is the liver through the portal tract, but sometimes the larvae go through the liver barrier and get to the lungs and all the other viscera, where they convert into small cysts [4, 5].

Hydatid cysts caused by *E. granulosus* is also called unilocular cyst. This rounded cyst is filled with liquid and it is made up of three layers: inner layer, outer layer and fibrosis layer. Inner layer produces Protoscoleces by asexual reproduction, then these protoscoleces developed to adult worm when they are eaten by the infinitive host [6].

The inner layer, also called germinal layer is 10-20 μm thick and it consists of nucleated cells. If the germinal layer is intact, it acts like a filter and prevents the entrance of hostile inflammatory cells and microorganisms, while the needed food for the parasites passes through it. The outer layer or laminated layer is a hard, elastic layer without any cell whose thickness ranges from 0.2 – 2 μm . This layer is secreted by germ layer and has a role in the protection of cysts [7, 8].

The fibrosis layer which surrounds the hydatid cyst, is a product of an inflammatory response in the first stage of cyst growth. The severity of this inflammatory response varies from one host to another which affects the cyst. If the response is intense, it causes the destruction and death of the parasite. whilst in the proper intermediate host, the initial response will disappear and a fibrous capsule will remain [9].

Hydatid cysts in humans develops most frequently in the liver (65%) and lungs (25%). The extra-pulmonary and extra hepatic sites are rare, thus they are mostly described as atypical or unusual by most of the authors or even ectopic and aberrant by some [10, 11]. Although thyroid hydatid cysts are usually associated with hepatic and pulmonary involvement, isolated involvement of the thyroid gland is very rare even in Iran and may be

*Corresponding author: Seyed Jafar Adnani Sadati, Dept. of Medical Microbiology and Immunology, Faculty of Medicine, Qom University of Medical Sciences, Qom, Iran, E-mail: Jafaradnani@yahoo.com

Mohsen Eshraghi, Ladan Shahmoradi: Dept. of surgery, Sh. Beheshty Hospital, Faculty of Medicine, Qom University of Medical Sciences, Qom, Iran

Mahdiieh Ghoddoosi: Dept. of Clinical Pathology Sh. Beheshty Hospital, Faculty of Medicine, Qom University of Medical Sciences, Qom, Iran

confused with malignancies [12, 13]. The cysts can be located in every organs and the symptoms of the disease differ greatly. These symptoms depend not only on the involved organs but also on the size of the cyst, its location and the involvement of the growing cyst with the adjacent members. Most of the cysts are without clinical symptoms [14, 15]. These asymptomatic cysts may grow rapidly resulting in compressive and obstructive problems. In addition, the rupture of hydatid cysts can trigger complications such as anaphylaxis shock, and death [16]. Clinical treatment of hydatid cysts includes albendazole or mebendazole therapy in combination with either surgical resection [17, 18].

This study reports a case of a primary hydatid cyst located in the left lobe of the thyroid gland.

Ethics approval: The research related to human use has been complied with all the relevant national regulations, institutional policies and in accordance with the tenets of the Helsinki Declaration, and has been approved by the ethics committee of Shahid Beheshti Hospital (Ethics Code: IR.MUQ.REC.1393.100), Qom University of Medical Sciences, Qom, Iran.

Informed consent: Informed consent has been obtained from the case (a 34-year-old woman) included in this study.

Case Presentation

A 34-year-old woman was presented to the general surgery clinic of our hospital complaining of a tangible nodule in the neck and infrequent hoarseness. Her neck swelling grew gradually and patient became aware of it a years ago. The patients past medical history highlighted there was a cerebrovascular accident (CVA) and she suffered from left hemiparesis. In physical examination, she had two mobile soft nodules with approximate sizes of 2×3 cm and 1×1 cm. Both were palpable in the left lobe of the thyroid which were not adhered to the surrounding tissues. There was no lymphadenopathy in the neck and the results of all examinations were normal. Thyroid ultrasonogram displayed both nodules in the left lobe, a larger one with echo free focus and cystic degeneration, and smaller bump with a thin wall but spectated that was echo free and seemed to be colloid cyst (Figure 1).

Not only did the hematologic and biochemistry laboratory tests reported normal, but also the thyroid function tests reported normal as well. FNA result was benign. Patient underwent left lobectomy and isthmectomy without any complications during surgery

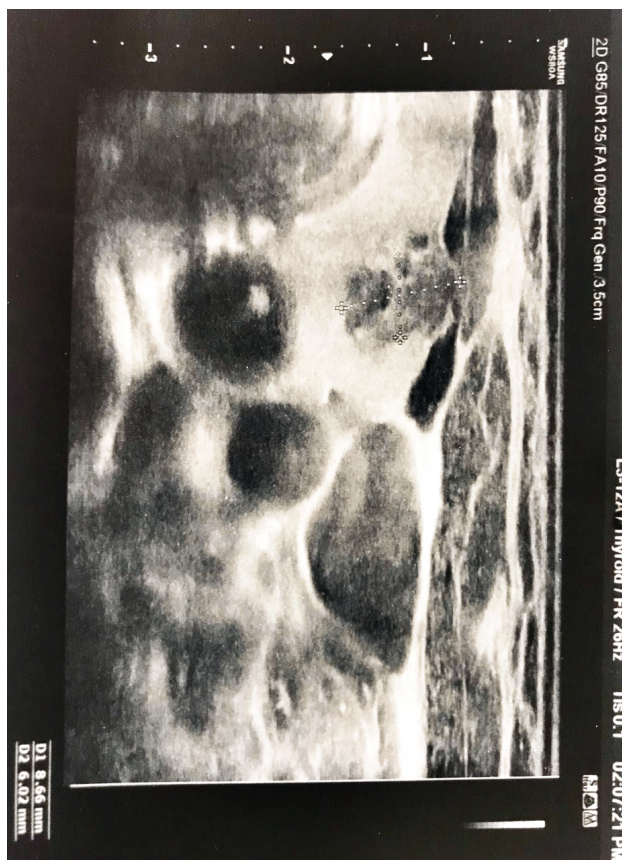

Figure 1: Thyroid ultrasonography showed a large lobulated cystic lesion in the left thyroid lobe.

or after it. In gross pathology, there was a 3 cm cystic nodule in the left lobe of the thyroid gland. There was a thick fibrous wall which separated the cysts from the surrounding thyroid parenchyma (Figure 2).

Histopathological examination reported nodular hyperplasia and a hydatid cyst in the left thyroid lobe (Figure 3).

B. Laminated fibrous cyst wall and protoscolex (star, inset), compatible with hydatid cyst

After surgery, the patient was examined, looking for any other cyst throughout other organs but fortunately there was no cystic lesion in the cranial, thoracic, or abdominal cavities and it seemed that it was just a case of primary thyroid hydatid cyst. The patient was dismissed from hospital a few days later with 400mg Albendazole per day administered for 3 months postoperatively. Currently she has no signs of recurrence.

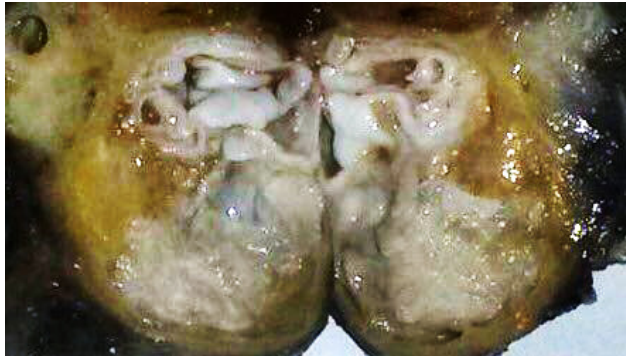

Figure 2: A cystic lesion with smooth whitish wall in lower pole left thyroid lobe.

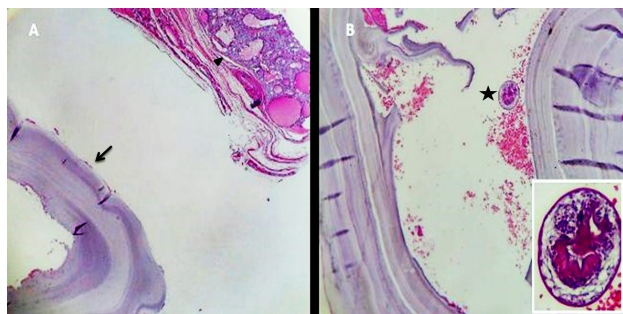


Figure 3: A. Laminated fibrous cyst wall (arrow) adjacent to thyroid tissue (arrow head).

Discussion

Hydatidosis in humans is a zoonotic infection caused by larval stages of cestode species of the genus *Echinococcus*. Cystic echinococcosis (CE) or unilocular cyst caused by *Echinococcus granulosus*, alveolar echinococcosis (AE) is caused by *E. multilocularis*, and polycystic forms are caused by either *E. vogeli* or *E. oligarthrus*. The most common of them were *E. granulosus*, and *E. multilocularis* is relatively rare although it is more virulent [19].

Hydatidosis is endemic throughout Iran with prevalence rate of 0.6-1.2 in 100000 population. Hydatidosis patients predominantly reside in rural areas, where people work closely with livestock [20, 21].

The life cycle of the parasite has three separate developmental stages including adult worms in the definitive host intestines, its eggs in the environment, and the metacestode (hydatid cyst) in the intermediate host. Carnivores, especially dogs, are the definitive hosts and common intermediate hosts are sheep, goats, cattle, camel and pig. Human may act as an accidental intermediate host [16, 22].

These hydatid cysts develop in their inner chamber, a structure known as protoscolex. The definitive host becomes infected by ingesting the cyst-containing organs of the infected intermediate host. After ingestion, the evaginated protoscolices, attach to the intestinal mucosa, and develop into adult stages in 32 to 80 days. Adult worm resides in the small intestine and releases eggs that contaminate the environment. After ingestion by intermediate host such as humans the egg hatches in the small bowel and releases an oncosphere that penetrates the intestinal wall and migrates through the circulatory system into various organs, especially the liver and lungs. In these organs, the oncosphere develops into a cyst [23].

Accordingly, Metacestodes or hydatid cysts are mostly located in the liver (60%) and lungs (30%) while they may also infect brain, bones, spleen, kidneys, pancreas, heart, muscles, adrenal and any other organ [24, 25]. The parasitic embryo can enter the systemic circulation and locate in the thyroid gland after either bypassing or passing through (primary and secondary type) the hepatic microcirculation. A high blood flow rate in the thyroid gland may be in charge of this problem. However, the small diameter of the thyroid arteries causes the rarity of the disease [26, 27].

There are some unusual localization of hydatid cyst in highly endemic countries for this parasitosis. Only 6 cases of 17 cases of hydatid cyst collected over 2 years in India, were located in unusual organs in the study of Illuri, et al [28]. A case of hydatid cyst of pancreas which is extremely rare was reported by Ozsay, et al [29]. Another unusual localization of hydatid cyst is reported in axillary region by Karadeniz, et al [30]. Another rare case of unusual localization of hydatid cyst is in ovaries in the study of Zhao, et al [31].

Atypical localization of hydatid cysts in the thyroid gland is rare. Involvement of the thyroid happens in only 1-2% of patients with hydatid disease in their liver or lungs.

Actually, no cases of thyroid hydatid cyst were reported in the Tunisian series of Bellil, et al [32]. In the southern part of Turkey, just one case of thyroid hydatid cyst was reported in the study of Akcam, et al [33]. The incidence of hydatid cysts in thyroid gland was claimed to be 0.5- 1% in turkey [34]. Thyroid hydatid cyst disease is generally asymptomatic when the size cysts increases, it may adhere to the surrounding structures, such as trachea, esophagus, carotid sheath, recurrent laryngeal nerve, and the strap muscles, in a similar manner to thyroid carcinoma [12, 35]. As a result, the patient may have the pressure symptoms and signs such as dyspnea, paralysis of the vocal cord, hoarseness, or dysphagia [2, 12, 36].

In echinococcosis cases, the diagnosis is mainly made on the patient history, physical examination, clinical observation, imaging methods, serologic tests, and FNA under the guide of ultrasound. Imaging methods generally include ultrasonography, CT scan, and MRI. Serologic tests include indirect hemagglutination, latex agglutination, ELISA, and immune electrophoresis. The gold standard method for accomplishment of diagnosis remains post-surgical histopathology [36, 37].

The most effective treatment of thyroid hydatid cyst is exclusively surgical excision. The aim of surgery is to prevent the spread of its contents and to remove the cyst entirely. If surgical treatment is not possible due to the patient's overall condition, treatment with Mebendazole or Albendazole may be attempted. The patient must be followed up for years because anti-parasite drugs eliminate live parasites and prevent contamination by cyst contents during surgery, rather than a cure [38-40].

In this case, a painless, movable nodule on the neck was the only symptom therefore we considered it as nodular goiter thanks to the nodular appearance in patient ultrasonogram (cystic generation and colloid cyst) and FNA result (benign thyroid lesion). Consequently, the patient went through left lobectomy and isthmectomy on the base of our primary and almost definite diagnosis. Since thyroid hydatid cyst are extremely rare it is easily misdiagnosed [29, 31], therefore we did not primarily regard it as a thyroid hydatid cyst disease, accordingly we did not conduct any serological and biochemical tests for hydatid disease. In another reported case by Karadeniz, et al, since axillary hydatid cyst is so much rare like our case, they did not initially diagnose it as hydatid cyst, therefore, they did not perform serological test as well [30, 41].

By the exact observation of the patient's nodular goiter and precise inspection during surgery and by post-surgical histopathologic examination, we finally diagnosed it as a hydatid cyst for definite diagnosis.

Conclusion

The present case indicates the presence of hydatid cysts in atypical anatomical locations in endemic regions. We should keep hydatidosis of thyroid in our mind when evaluating cystic nodules of the thyroid gland. We hope that this rare case may provide a practical example of atypical signs and symptoms of hydatid cysts.

Conflict of interest: Authors state no conflict of interest

References

1. Sadati SJA, Farahnak A, Rad MBM, Golestani A, Eshraghiyan MR. A Comparison between the Effects of Albendazole and Mebendazole on the Enzymatic Activity of Excretory/Secretory Products of *Echinococcus granulosus* Protoscoleces in Vitro. *Iranian journal of public health* 2016;45(2):223-9.
2. Sayek I, Onat D. Diagnosis and treatment of uncomplicated hydatid cyst of the liver. *World J Surg* 2001;25:21-7.
3. Rokni M B. Echinococcosis/hydatidosis in Iran. *Iran J Parasitol* 2009;4(2):1-6.
4. Romig T. Epidemiology of echinococcosis. *Langenbeck's archives of surgery* 2003;388(4):209-17.
5. Gossios K, Kontoyiannis D, Dascalogiannaki M, Gourtsoyiannis N. Uncommon locations of hydatid disease: CT appearances. *European radiology* 1997;7(8):1303-8.
6. Li ZJ, Zhao W. Analysis of protoscoleces-specific antigens from *Echinococcus granulosus* with proteomics combined with Western blot. *Biomedical and environmental sciences :BES* 2012;25(6):718-23.
7. Pawlowski Z. Echinococcosis in humans: clinical aspects, diagnosis and treatment. WHO/OIE Manual on echinococcosis in humans and animals. 2001.
8. Eckert J, Gemmel M, Meslin F-X, Pawlowski Z. WHO-OIE manual on Echinococcosis in humans and animals: a public health problem of global concern. World organisation for animal health Paris; 2001.
9. Thompson R. Biology and systematics of *Echinococcus*. *Echinococcus and hydatid disease. Advances in Parasitology* 1995.
10. Gun E, Etit D, Buyuktalanci DO, Cakalagaoglu F. Unusual locations of hydatid disease: A 10-year experience from a tertiary reference center in Western Turkey. *Annals of diagnostic pathology* 2017;29:37-40.
11. Saadi A, Bouzouita A, Cherif M, Rebai MH, Walid Kerkeni, Haroun Ayed, et al. Retrovesical hydatid cyst: About 4 cases. *Can Urol Assoc J* 2015;9(5-6):374-8.
12. Chetty R, Crowe P, Cant P. An unusual thyroid cyst. A case report. *South African journal of surgery Suid-Afrikaanse tydskrif vir chirurgie* 1991;29(4):158-9.
13. Moghimi M, Kamrava SK, Behzadi AH, Asghari AM, Jalessi M, Naraghi MM, et al. Primary echinococcal cyst in the thyroid gland: a case report from Iran. *The Journal of Infection in Developing Countries* 2009;3(09):732-4.
14. Frider B, Larrieu E, Odriozola M. Long-term outcome of asymptomatic liver hydatidosis. *Journal of Hepatology* 1999;30(2):228-31.
15. Keshmiri M, Baharvahdat H, Fattahi S, Davachi B, Dabiri R, Baradaran H, et al. Albendazole versus placebo in treatment of echinococcosis. *Transactions of the Royal Society of Tropical Medicine and Hygiene* 2001;95(2):190-4.
16. Eken H, Isik A, Balci G, Firat D, Cimen O, Soyuturk M. A rare case of isolated cystic hydatid of thyroid gland. *Medicine* 2016;95(10):1-3.
17. Bekçi TT. Diagnosis and treatment of human hydatid disease. *Eur J Gen Med* 2012;9:15-20.
18. Meshkibaf MH, Abdollahi A, Fasihi Ramandi M, Adnani Sadati SJ, Moravvej A, Hatami S. Antibacterial effects of hydro-alcoholic extracts of *Ziziphora tenuior*, *Teucrium*

- polium, *Barberis corcorde* and *Stachys inflata*. *Koomesh* 2010;11(4):240-4.
19. Eckert J, Deplazes P. Biological, epidemiological, and clinical aspects of echinococcosis, a zoonosis of increasing concern. *Clinical microbiology reviews* 2004;17(1):107-35.
 20. Shoaee S, Rezvanizadeh M, Haghighi M, Yousefi H. Epidemiological, Clinical and Paraclinical Study of Hydatid Cysts in Three Educational Medical Centers in 10 Years. *Novelty in Biomedicine* 2016;4(1):28-33.
 21. Dahniya M, Hanna R, Ashebu S, Muhtaseb S, El-Beltagi A, Badr S, et al. The imaging appearances of hydatid disease at some unusual sites. *The British journal of radiology* 2001;74(879):283-9.
 22. Gavara CG, López-Andújar R, Ibáñez TB, Ángel JMR, Herráiz ÁM, Castellanos FO, et al. Review of the treatment of liver hydatid cysts. *World Journal of Gastroenterology: WJG* 2015;21(1):124.
 23. McManus DP, Zhang W, Li J, Bartley PB. Echinococcosis. *The Lancet* 2003;362(9392):1295-304.
 24. Ezer A, Zafer Nursal T, Moray G, Yildirim S, Karakayali F, Noyan T, et al. Surgical treatment of liver hydatid cysts. *HPB* 2006;8(1):38-42.
 25. Eken H, Isik A, Balci G, Firat D, Cimen O, Soyuturk M. A Rare Case of Isolated Cystic Hydatid of Thyroid Gland. *Medicine* 2016;95(10):1-3.
 26. Gökçe C, Patiroğlu T, Akşehirli S, Durak AC, Keleştimur F. Hydatid cyst in the thyroid gland diagnosed by fine-needle aspiration biopsy. *Thyroid* 2003;13(10):987-9.
 27. Rauhofer U, Prager G, Hörmann M, Auer H, Kaserer K, Niederle B. Cystic echinococcosis of the thyroid gland in children and adults. *Thyroid* 2003;13(5):497-502.
 28. Illuri HR, Souza CD, Dias EA, Das PP. Hydatid disease: a 2 years retrospective study in a tertiary care center in South India. *International Surgery Journal* 2018;5(2):602-7.
 29. Ozsay O, Gungor F, Karaisli S, Kokulu I, Dilek ON. Hydatid cyst of the pancreas causing both acute pancreatitis and splenic vein thrombosis. *The Annals of The Royal College of Surgeons of England* 2018;100(7):178-80.
 30. Karadeniz E, Mesut Y, Akcay MN, Atamanalp SS. Primary Hydatid Cyst in the Axillary Region: A Case Report. *Iranian journal of parasitology* 2018;13(2):328-30.
 31. Zhao Q, Luo J, Zhang Q, Leng T, Yang L. Laparoscopic surgery for primary ovarian and retroperitoneal hydatid disease: A case report. *Medicine*. 2018;97(3):e9667.
 32. Bellil S, Limaïem F, Bellil K, Chelly I, Mekni A, Haouet S, et al. Descriptive epidemiology of extrapulmonary hydatid cysts: a report of 265 Tunisian cases. *La Tunisie Medicale* 2009;87(2):123-6.
 33. Akcam AT, Ulku A, Koltas IS, Izol V, Bicer OS, Kilicbagir E, et al. Clinical characterization of unusual cystic echinococcosis in southern part of Turkey. *Annals of Saudi medicine* 2014;34(6):508-16.
 34. Bartın MK, Yılmaz EM, Arslan H, Tekeli AE, Karataş S. A case of primary hydatid cyst in the thyroid gland. *Turkish Journal of Surgery/Ülusal cerrahi dergisi* 2015;31(2):94-95.
 35. Banazadeh M, Eshraghi M, Rahim MB, Alavi AA, Valeshabad AK. Successful management of acute necrotizing mediastinitis with trans-cervical drainage. *Annals of Thoracic and Cardiovascular Surgery* 2011;17(5):498-500.
 36. Jain S, Jamdade P, Muneshwar S, Ambulgekar V, Panzade S. Hydatid cyst of thyroid: an unusual cause of stridor. *Indian Journal of Otolaryngology and Head and Neck Surgery* 2005;57(1):80-1.
 37. Bouckaert M, Raubenheimer E, Jacobs F. Maxillofacial hydatid cysts. *Oral Surgery, Oral Medicine, Oral Pathology, Oral Radiology, and Endodontology* 2000;89(3):338-42.
 38. Gurses N, Baysal K, Gurses N. Hydatid cyst in the thyroid and submandibular salivary glands in a child. *ZK inderchir* 1986;41:362-3.
 39. Sahni JK, Jain M, Bajaj Y, Kumar V, Jain A. Submandibular hydatid cyst caused by *Echinococcus oligarthrus*. *J Laryngol Otol* 2000;114:473-6.
 40. Smego RA, Sebanego P. Treatment options for hepatic cystic echinococcosis. *Int J Infect Dis* 2005;9:69-76.
 41. Ozsoy M, Keles C, Kahya M, Keles G. Primary echinococcal cyst in the axillary region. *The Journal of Infection in Developing Countries* 2011;5(11):825-7.